

6-2016

# Histomorphometric Analysis of Maxillary Sinus Grafts: A Randomized Controlled Study

Mina Nishimoto

Follow this and additional works at: <http://scholarsrepository.llu.edu/etd>

 Part of the [Dentistry Commons](#)

---

## Recommended Citation

Nishimoto, Mina, "Histomorphometric Analysis of Maxillary Sinus Grafts: A Randomized Controlled Study" (2016). *Loma Linda University Electronic Theses, Dissertations & Projects*. 355.  
<http://scholarsrepository.llu.edu/etd/355>

This Thesis is brought to you for free and open access by TheScholarsRepository@LLU: Digital Archive of Research, Scholarship & Creative Works. It has been accepted for inclusion in Loma Linda University Electronic Theses, Dissertations & Projects by an authorized administrator of TheScholarsRepository@LLU: Digital Archive of Research, Scholarship & Creative Works. For more information, please contact [scholarsrepository@llu.edu](mailto:scholarsrepository@llu.edu).

LOMA LINDA UNIVERSITY  
School of Dentistry  
in conjunction with the  
Faculty of Graduate Studies

---

Histomorphometric Analysis of Maxillary Sinus Grafts:  
A Randomized Controlled Study

by

Mina Nishimoto

---

A dissertation submitted in partial satisfaction of  
the requirements for the degree  
Master of Science in Implant Dentistry

---

June 2016

Copyright © 2016

Mina Nishimoto  
All Rights Reserved

Each person whose signature appears below certifies that this thesis in his/her opinion is adequate, in scope and quality, as a thesis for the degree Master of Science.

\_\_\_\_\_, Chairperson  
Joseph Y. K. Kan, Professor of Restorative Dentistry

\_\_\_\_\_  
Jaime L. Lozada, Professor of Implant Dentistry

\_\_\_\_\_  
Phillip Roe, Assistant Professor of Restorative Dentistry

\_\_\_\_\_  
Kitichai Rungcharassaeng, Professor of Orthodontics and Dentofacial Orthopedics

## ACKNOWLEDGEMENTS

I would like to express my deepest gratitude to the members of my research committee for their advice, direction, and inspiration. I would also like to thank the faculty members, residents, and staff of the Advanced Education Program in Implant Dentistry for their support throughout the study. I would like also to acknowledge Dr. Udochukwu Oyoyo for his assistance in the statistical analysis and Dr. Hari Prasad for his work involving the histomorphometric analysis. Finally, I would like to thank my parents; Takeo Nishimoto, my father for his understanding and support while I pursued my dreams and Naoko Nishimoto, my mother, for waiting these years with such love and patience.

# CONTENT

Approval Page.....	iii
Acknowledgements.....	iv
List of Figures.....	vii
List of Tables.....	ix
List of Abbreviations.....	x
Abstract.....	xi
Chapter	
1. Introduction.....	1
2. Material and Methods.....	3
Patient Selection.....	3
Inclusion Criteria.....	3
Exclusion Criteria.....	3
Study Design and Treatment Groups.....	4
Informed Consent.....	5
Randomization.....	6
Patient and Site Withdrawal and/or Replacement.....	6
Clinical Procedures.....	6
Diagnosis and Treatment plan.....	6
Preoperative Procedures.....	7
Surgical Procedures.....	8
Post-operative instructions.....	12
Surgical and post-operative complications.....	13
Biopsy Procedure.....	13
Histology.....	16
Histomorphometric Analysis.....	17
Statistic Analysis.....	17
3. Results.....	19
Clinical Results.....	19
Results: Histomorphometric Analysis.....	22

Results: Histologic Analysis .....	25
Group A .....	25
Group B .....	26
Group C.....	27
4. Discussion and Conclusions .....	29
Discussion.....	29
Conclusions.....	33
References.....	34

## FIGURES

Figures	Page
1. Study flowchart.....	5
2. Pre-operative view in Group A.....	11
3. Complete removal of the lateral sinus bone wall. Checking the integrity of maxillary sinus membrane visually and by Valsalva maneuver.....	11
4. Indexed template for partially edentulous site.....	11
5. Measurement of the inferior border of the window with the aid of template.....	11
6. Measurement of the superior border of the window with the aid of template.....	12
7. Graft material placement in Group A (Bio-Oss®).....	12
8. Graft material placement in Group B (Equimatrix®).....	12
9. Graft material placement in Group C (OSSIF-i sem™).....	12
10. Post-operative CBCT image.....	14
11. Appearance of lateral window following 9 months of healing in Group A.....	14
12. Locating area for biopsy using periodontal probe and template.....	14
13. Bone core in a trephine (Bio-Oss®).....	15
14. Appearance of lateral window following 9 months of healing in Group B.....	15
15. Bone core in a trephine (Equimatrix®).....	15
16. Appearance of lateral window following 9 months of healing in Group C.....	15
17. Bone core in a trephine (OSSIF-i sem™).....	15
18. Low-power view of photomicrograph of ABBM.....	26
19. High-power view of photomicrograph of ABBM.....	26
20. Very high-power view of photomicrograph of ABBM.....	26
21. Low-power view of photomicrograph of AEBM.....	27



22. High-power view of photomicrograph of AEBM.....	27
23. Very high-power view of photomicrograph of AEBM.....	27
24. Low-power view of photomicrograph of MCBA .....	28
25. High-power view of photomicrograph of MCBA .....	28
26. Very high-power view of photomicrograph of MCBA .....	28

## TABLES

Tables	Page
1. Patient demographics and surgical site distribution.....	20
2. Intraoperative and postoperative complications .....	21
3. Bone quality during biopsy at grafted sites.....	22
4. Histomorphometric analysis of the three groups of graft materials.....	23
5. Histomorphometric comparison of the percentage of vital bone, residual bone material and marrow/connective tissue among the groups .....	24

## ABBREVIATIONS

ABBM	Anorganic bovine bone mineral
AEBM	Anorganic equine bone mineral
CBCT	Cone-beam computed tomography
CT	Connective tissue / marrow
CT %	Percentage of connective tissue / marrow
IRB	Institutional review board
LA	Local anesthesia
MCBA	Mineralized cancellous bone allograft
MSG	Maxillary sinus grafts
RBM	Residual bone material
RBM %	Percentage of residual bone material
SPSS	Statistical package for the social science
VB	Vital bone
VB %	Percentage of vital bone

## ABSTRACT OF THE MASTER THESIS

Histomorphometric Analysis of Maxillary Sinus Grafts:

A Randomized Controlled Study

by

Mina Nishimoto

Master of Science, Advanced Education Program in Implant Dentistry

Loma Linda University, June 2016

Dr. Joseph Y. K. Kan, Chairperson

The purpose of this clinical investigation was to evaluate and compare the degree of new bone formation through histomorphometric analysis following maxillary sinus grafts (MSG) using three different bone graft materials. Thirty-one MSG were performed using a lateral window approach for patients who required implant placement in posterior maxilla. Each sinus was randomly selected to receive one of three bone graft materials; Group A: anorganic bovine bone mineral (ABBM) [Bio-Oss<sup>®</sup>], Group B: anorganic equine bone mineral (AEBM) [Equimatrix<sup>®</sup>], or Group C: mineralized cancellous bone allograft (MCBA) [OSSIF-i sem<sup>™</sup>]. A total of 28 bone cores were obtained at a mean time of 9.1 months following MSG and used for the histomorphometric analysis. The quality of bone was also estimated (Lekholm & Zarb 1985) during biopsy using a trephine bur.

Histologically, newly formed bone showed close contact to the residual graft materials and interconnected the bone particles in all groups. Histomorphometric analysis revealed statistically significant differences in the percentage of vital bone

(VB%) among three groups (Kruskal Wallis,  $P = .001$ ). The observed VB% was significantly lower [ $P = .004$ ] in Group A ( $10.9 \pm 8.9\%$ ) and also lower [ $P = .001$ ] in Group B ( $9.1 \pm 5.9\%$ ) as compared to Group C ( $32.0 \pm 12.4\%$ ). No significant difference in VB% was noted between Group A and Group B [ $P = 1.0$ ].

Within the confines of this study, a statistically significant difference in new bone formation was noted among the three graft materials at a mean follow-up period of 9.1 months following MSG. The MCBA (OSSIF-i sem<sup>TM</sup>) group revealed significantly greater new bone formation when compared to the ABBM (Bio-Oss<sup>®</sup>) and AEBM (Equimatrix<sup>®</sup>) groups. The AEBM showed comparable histomorphometric results in all parameters (VB%, RBM%, CT) when compared to ABBM. Bone quality was greater in ABBA and AEBM groups in comparison to the MCBA group indicating the greater VB% does not directly translate to improved bone quality.

## **CHAPTER ONE**

### **INTRODUCTION**

Maxillary sinus grafts (MSG) is a common and predictable procedure used to increase bone height for implant placement in the posterior maxilla and numerous bone graft materials have been advocated and used for the MSG (Jensen et al. 1998; Wallace & Froum 2003; Pjetursson et al. 2008; Del Fabbro et al. 2013). The viability of these graft materials are often defined via histomorphometric analysis.

Boyne and James first described MSG using autogenous bone harvested from the iliac crest (Boyne & James 1980). Since then, autogenous bone was considered as the “gold standard” for MSG due to its osteogenic potential (Moy et al. 1993; Lorenzetti et al. 1998; Hallman et al. 2002; Crespi et al. 2007). Unfortunately, procuring autogenous bone from various sites (chin, ramus, iliac crest, calvaria) can possibly increase the risk of morbidity and discomfort (Kalk et al. 1996; Johansson et al. 2001; Nkenke et al. 2001, 2004). Because of that, non-autogenous bone graft materials (xenograft, allograft and alloplast) have been suggested for MSG procedures (Smiler & Holms 1987; Smiler et al. 1992; Boyne 1993; Moy et al. 1993; Wallace et al. 1996; Wheeler 1997; Valentini et al. 1998; Scher et al. 1999; van den Bergh et al. 2000).

Xenograft is the most frequently evaluated non-autogenous bone graft material for MSG and anorganic bovine bone material (ABBM) [Bio-Oss<sup>®</sup>, Geistlich, Princeton, NJ] is the most studied xenograft material (Piattelli et al. 1999; Valentini et al. 2000; Wallace et al. 2005; Cordaro et al. 2008; Testori et al. 2013). Implant has shown high success in xenograft despite of its osteoconductive property (Aghaloo & Moy 2007; Jensen et al 2012). Another xenograft material, anorganic equine bone mineral (AEBM) has been

recently introduced (Arteste et al. 2011; Nevins et al. 2013; Di Stefano et al. 2015, 2016). A multicenter case series found the percentage of vital bone after the healing of AEBM (Equimatrix<sup>®</sup>, Osteohealth, Shirley, NY) in MSG seemed to be comparable that of ABBM (Nevins et al. 2013). To date, there is limited information available with regard to AEBM or comparison studies between AEBM and ABBM.

Allograft is another bone graft material used for MSG (Scher et al. 1999; van den Bergh et al. 2000; Noubissi et al. 2005; Froum et al. 2006; Soardi et al. 2011; Kolerman et al. 2012). The osseoinductive nature of allograft may promote new bone formation. Froum et al. (2006) compared the efficacy of allograft (MCBA)(Puros<sup>®</sup>) to xenograft (ABBM)(Bio-Oss<sup>®</sup>) in new bone formation in MSG, found significantly greater vital bone in MCBA group as compared to the ABBM group (Froum et al. 2006).

The purpose of this randomized clinical investigation was to compare new bone formation using histomorphometric analysis of two xenograft [ABBM (Bio-Oss<sup>®</sup>), AEBM (Equimatrix<sup>®</sup>)] and, one allograft MCBA (OSSIF-i sem<sup>™</sup>) material following MSG. The null hypothesis was that there was no histomorphometric difference in new bone formation among the groups.

## **CHAPTER TWO**

### **MATERIAL AND METHODS**

#### **Patient Selection**

This prospective clinical randomized controlled study was approved by the Institutional Review Board (IRB) of Loma Linda University (IRB #5130213) and was conducted at the Center for Implant Dentistry, Loma Linda University, School of Dentistry, California. Patients who required MSG prior to implant placement were invited to participate in this study if they met the following criteria.

#### ***Inclusion Criteria***

1. Patients 18 years or older who are able to read and sign a written consent form.
2. Patients who possess partially or completely edentulous posterior maxilla requiring MSG via lateral window approach (unilateral or bilateral) in preparation for implant placement.
3. Patients who would be available for a period of approximately 8 months for follow-up appointments, biopsy, and subsequent implant placement.

#### ***Exclusion Criteria***

1. Patients who presented with a medical history that would complicate surgical procedures and/or the outcome of the study such as history of head and neck radiation treatment, uncontrolled diabetes, uncontrolled hypertension, uncontrolled blood disorder, alcohol or drug dependency, immunodeficiency diseases or any other medical and psychological conditions.



2. Signs or symptoms of maxillary sinus disease.
3. History of smoking.
4. Pregnancy.
5. Poor oral hygiene.

### ***Study Design and Treatment Groups***

Thirty maxillary sinuses were included and randomly allocated into three equal treatment groups (Group A, B or C; n = 10 each group) according to the graft material to be used. The treatment groups are as follow;

- Group A (Control): ABBM (Bio-Oss<sup>®</sup>, Geistlich, Princeton, NJ).
- Group B (Test): AEBM (Equimatrix<sup>®</sup>, Osteohealth, Shirley, NY).
- Group C (Test): MCBA (OSSIF-i sem<sup>™</sup>, Osteohealth, Shirley, NY.)

Figure 1 shows a flowchart of the study.

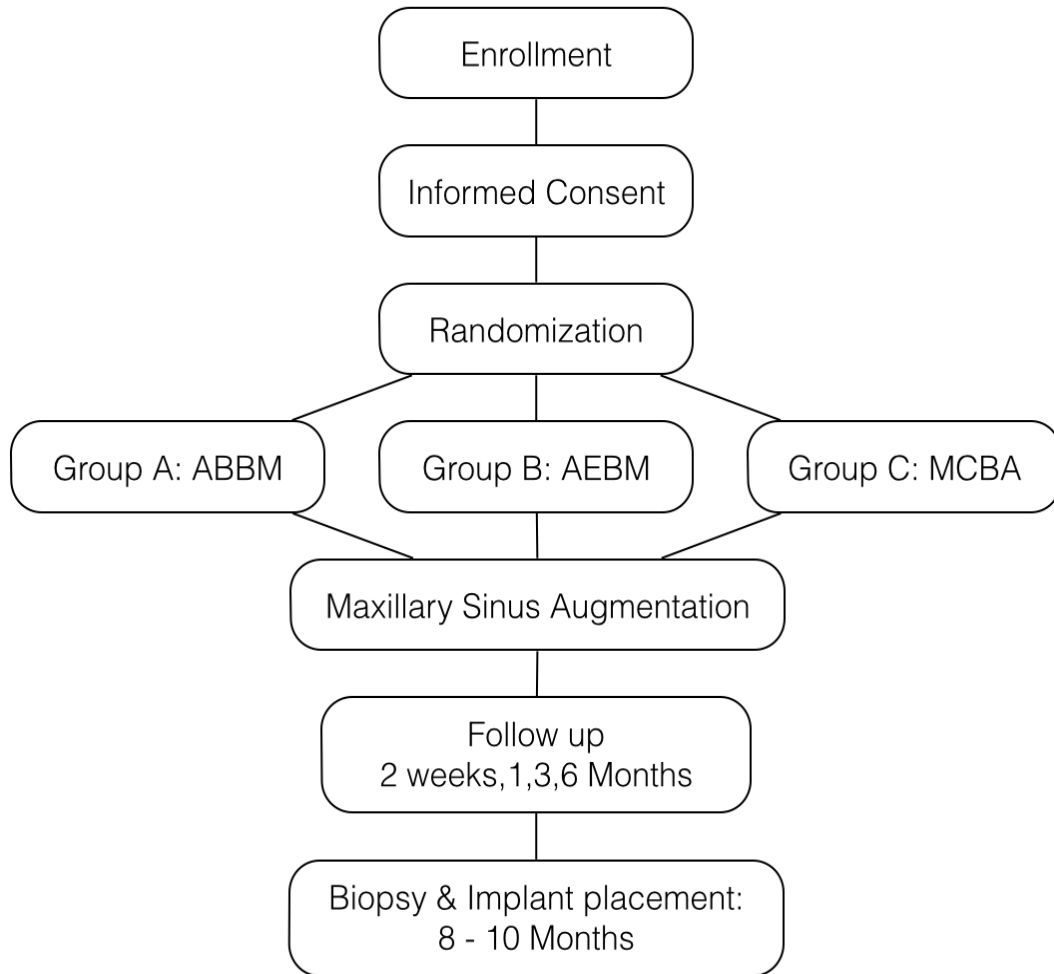


Figure 1. Study flowchart

### ***Informed Consent***

In accordance with the standards of conduct established by the IRB of Loma Linda University, participants were required to sign an informed consent. The purpose and the nature of the study were explained to the patients and patients who met our inclusion criteria participated in the study. Patients were required to read, understand, and sign the consent form before being enrolled in the study.

### ***Randomization***

Randomization was performed by one investigator (MN) using Research Randomizer (Version 4.0) software (Geoffrey C. Urbaniak and Scott Plous; <http://www.randomizer.org>) at the time of enrollment in the study. In event of a bilateral MSG, each maxillary sinus was randomly assigned different treatment groups.

### ***Patient and Site Withdrawal and/or Replacement***

A maxillary sinus was removed from the study and replaced if:

1. Perforation of the maxillary sinus membrane equal to or greater than 5 mm in diameter was observed during the sinus surgery,
2. Infection was noted during the healing phase after the surgery.

If a patient was unable to attend the designated post-operative follow-up appointments or was uncooperative, the patient and the corresponding sinus(es) was dismissed from the study.

### **Clinical Procedures**

#### ***Diagnosis and Treatment plan***

1. Preliminary impressions were made using a polyvinylsiloxane impression material (Exafast, GC America Inc., Alsip, IL) and the corresponding diagnostic casts were fabricated using a type III dental stone (Microstone, Whip Mix, Louisville, KY).
2. Diagnostic casts were articulated using a face-bow transfer to a Panadent semi-adjustable articulator (Panadent Corporation, Colton, CA). An interocclusal record was made using either wax occlusion rim(s) and/or polyvinylsiloxane (Exabite, GC America Inc., Alsip, IL).

3. Diagnostic waxing of the missing teeth was made using a tooth-color wax (Pro-Art, Ivoclar Vivadent, Inc., Williams, Amherst, NY) and then duplicated with a type III dental stone for partially edentulous patients. Conventional dentures were fabricated for the completely edentulous patients using conventional techniques. A silicone index of the denture setup was created using condensation silicone lab putty (Polysiloxane Coltene Lab-Putty, Coltene Whaledent Inc. Cuyahoga Falls, OH).
4. A vacuum-formed radiographic template (Polypropylene Coping Sheet, Ultradent Products, South Jordan, UT) with auto-polymerizing acrylic resin (Jet, radiopaque teeth color, Lang Dental, Wheeling, IL) was created using the duplicated cast in partially edentulous patients. A radiographic template for completely edentulous patients was duplicated from the silicone index. Radiopaque color auto-polymerizing acrylic resin was used for teeth and clear color was used for the base.
5. All patients underwent a cone-beam computed tomography (CBCT) scan (i-CAT™ Cone Beam 3-D Imaging System, Imaging Sciences International, Inc. Hatfield, PA) was taken with the radiographic template in place.
6. An additional template was fabricated for each patient using the same duplicated cast or silicone index. These templates were indexed using groove(s) to locate the proposed biopsy site on lateral window. All templates were fabricated by one of investigators (MN) (Figure. 4).

### ***Preoperative Procedures***

At the pre-surgical appointment, the patient's vital signs (blood pressure and pulse rate) were recorded and medical history was updated. Patients were given the following

choices of anesthesia for the MSG surgery:

- a) Local anesthesia (LA) only
- b) LA in conjunction with oral sedation (Halcion 0.25mg, Roxane Laboratories Inc., Columbus, OH)
- c) LA in conjunction with intravenous sedation

One patient chose intravenous sedation and had a pre-surgical interview with the anesthesiologist who conducted sedation at the time of the surgery. Seven patients opted for oral sedation. The remaining 13 patients chose to undergo the procedure using only LA.

Patients were questioned regarding drug allergy and prescribed appropriate antibiotics. None of the enrolled patients reported drug allergy and were prescribed Amoxicillin 500 mg (TEVA Pharmaceuticals USA, Sellersville, PA) for prophylaxis using 2 g amoxicillin 1 hour prior to the surgery and continuing 500 mg three times a day post surgically for 7 days. An analgesic (Ibuprofen 800 mg, American Health Packaging, Columbus, OH) was prescribed and the patient was instructed to take one tablet every 6 hours as needed with a maximum dosage of 3200 mg per day. To keep the surgical site clean, patients were instructed to rinse with 0.12% chlorhexidine gluconate solution (Peridex, Zila Pharmaceuticals Inc., Phoenix, AZ) twice a day, 3 days before the surgery and 2 weeks after the surgery.

### ***Surgical Procedures***

Residents who had been calibrated prior the performed maxillary sinus graft surgeries under the direct supervision of the principal investigator (JK). The principle

investigator reviewed the surgical approach prior to the surgery with all surgeons to ensure that there would be minimal variation between procedures.

Treatment sequence:

1. On the day of surgery, the patient was asked to rinse with a 0.12% chlorhexidine gluconate solution (Peridex) for one minute. After being seated, a blood pressure cuff and pulse oximeter was placed to monitor the patient's vitals during the surgery. The circumoral area was scrubbed with a povidone-iodine swab stick (Aplicare, Aplicare Inc., Branford, CT) and the patient was draped. Oxygen was administered to the patient using a nasal cannula at a rate of 3 liters/minute.
2. After establishing anesthesia, a mid-crestal incision and with two vertical incisions were made anteriorly and posteriorly at the appropriate location to allow enough visualization and access. A full-thickness mucoperiosteal flap was reflected to expose the lateral maxillary sinus wall.
3. A lateral window was first outlined using a sterile pencil to make sure the size is wide enough for further biopsy. The MSG would be performed via the lateral window approach either by removing the window completely using a dome shaped surgical diamond coated drill (DASK Drill #5; Dentium Advanced Sinus Kit, Dentium, Korea) or by outlining the proposed window with a slow speed carbide round bur (KOMET USA, Rock Hill, SC) and in-fracturing the lateral bone wall.
4. The lateral window was positioned approximately 3 mm from the maxillary sinus floor and 3 mm from the anterior wall of the maxillary sinus to allow the sinus curettes to reach the maxillary sinus floor and the anterior wall. The superior border was made approximately 15 mm higher from the alveolar crest to secure adequate amount of

graft for further biopsy (Figure 6). The posterior border of the window was made at the right distal to the last implant planned.

5. The maxillary sinus membrane was carefully elevated to create space for the bone graft. The integrity of the maxillary sinus membrane was inspected visually its integrity confirmed using the Valsalva maneuver. In the event of a perforation, the surgeon was instructed to proceed until the lateral window was complete and the appropriate displacement and reflection of the maxillary sinus membrane had been achieved. A perforation (< 5 mm in diameter) was repaired by means of a resorbable collagen membrane (Bio-Gide®, Geistlich Pharma North America Inc., Princeton, NJ) placing over the perforation with at least 3 mm overlaying unaffected membrane in all directions. Grafting procedure was continued following the repair. Any perforation equal to or greater than 5 mm was excluded from the study.
6. The inferior and superior border of the window were measured using the patient's indexed template along the groove(s) with a periodontal probe (Pearson Color-Coded Probe CP15UNC, Pearson Dental Supply Company, Sylmar, CA, or #12, South Dakota, Single End, Yellow, American Eagle Instruments, Missoula, MT). This would serve as the reference to locate the position of future biopsy site (Figure 4, 5, 6). The mesiodistal width of the lateral window was also measured.
7. Bone graft materials; ABBM (Small granules Cancellous, 0.25-1.0 mm), AEBM (Cancellous, Particle Size 0.2-1.0 mm), or MCBA (Small particles, 0.25-1.0 mm) were placed into a maxillary sinus compartment for each respective group (Figure 7, 8, 9).

8. A resorbable collagen membrane (Bio-Gide<sup>®</sup>) was measured, trimmed, and placed over the graft material to ensure that membrane would extend approximately 3 mm beyond the borders of the lateral window.
9. Flaps were approximated and primary closure was achieved using an expanded polytetrafluoroethylene (Gore-Tex, W.L. Gore and Associates, Inc. Newark, DE) suture for the crestal incision and coated polyglactin 910 suture (VICRYL<sup>®</sup> 6-0, Ethicon, Johnson & Johnson, Somerville, NJ) for the vertical incisions.

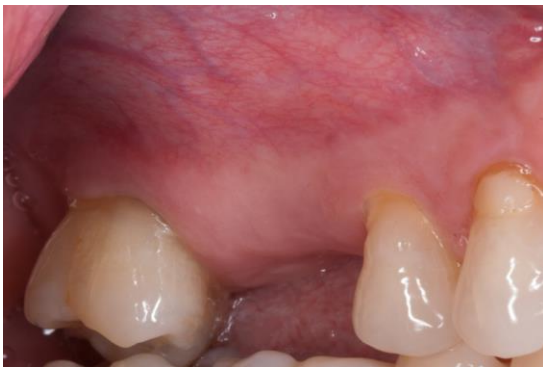

Figure 2. Pre-operative view in Group A

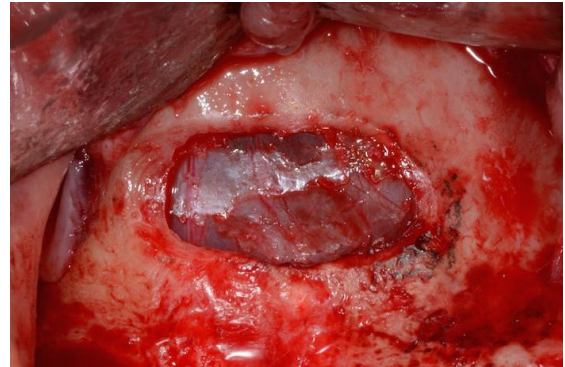


Figure 3. Complete removal of the lateral sinus bone wall. Checking the integrity of maxillary sinus membrane visually and by Valsalva maneuver

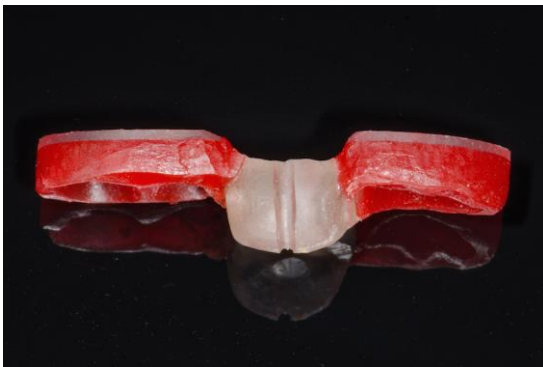

Figure 4. Indexed for partially edentulous site

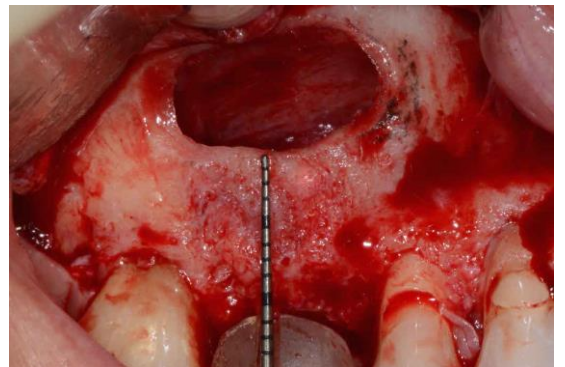


Figure 5. Measurement of the inferior border of the window with the aid of template



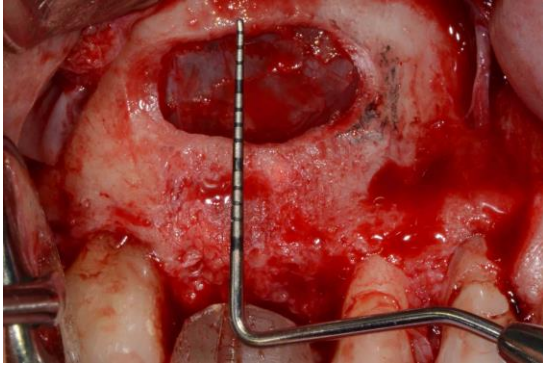


Figure 6. Measurement of the superior border of the window with the aid of template

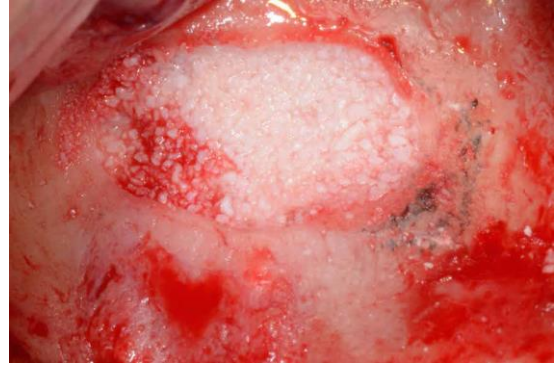

Figure 7. Graft material placement in Group A (Bio-Oss®)

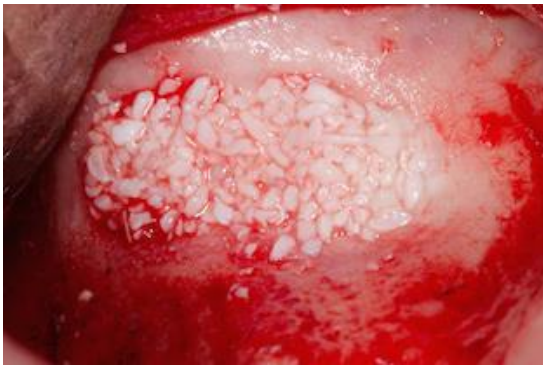

Figure 8. Graft material placement in Group B (Equimatrix®)

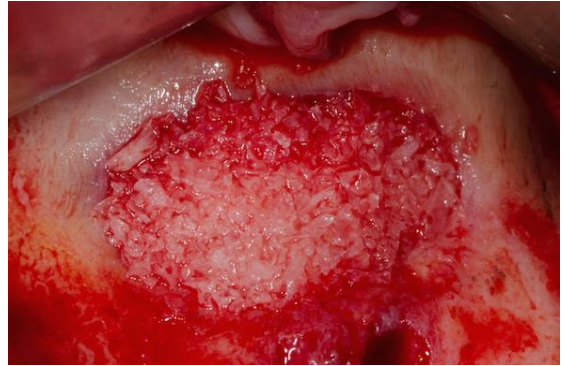

Figure 9. Graft material placement in Group C (OSSIF-i sem™)

### *Post-operative Instructions*

Patients were advised to avoid blowing their nose, placing any undue pressure on the surgical site, and were instructed to maintain a liquid diet for two weeks after the surgery. Following this two-week period, the patient was instructed to transition to a soft diet for one month and then continue to their general diet for the remainder of the healing phase. Patients were instructed to follow the prescribed intervals for medications that were dispensed at the pre-operative appointment. All removable prostheses were evaluated for proper tissue adaptation during the follow up period. In cases with poor tissue adaptation, the prosthesis was modified and readapted using a soft reline material

(GC Reline Soft, GC, Alsip, IL). Patients were scheduled two weeks following the surgery for suture removal and at 1, 3, and 6 months for subsequent follow up examinations.

### ***Surgical and Post-operative Complications***

Surgical and post-operative complications such as maxillary sinus membrane perforation, hemorrhage, wound opening, suppuration, acute or chronic graft infection and sinusitis were recorded.

### ***Biopsy Procedures***

1. A CBCT scan (i-CAT™, or NewTom VGi, NewTom, Verona, Italy) was taken two weeks prior to the biopsy and implant placement. The same radiographic template was utilized to evaluate the grafted site and to determine the final implant position, implant size and the location of biopsy (Figure.10).
2. Following a healing period of approximately 8 months, a full-thickness flap was reflected and the previous osteotomy site was located using the same template (Figure 11, 12, 14, 16). A trephine bur; 3.2 mm inner diameter, 4.0 mm outer diameter (Easyretrieve, ACE Surgical Supply Company, Inc., Brockton, MA) was used to collect a bone core with a minimum length of 8 mm within the previously prepared lateral window. The quality of bone was estimated (Lekholm & Zarb 1985) during biopsy using the trephine bur. The harvested bone core remained in the trephine bur was stored in 10% buffered formalin using a coded container (Figure 13, 15, 17). The coded bone samples were sent to an outside laboratory (Hard Tissue Research

Laboratory, University of Minnesota School of Dentistry) for histologic and histomorphometric analysis.

3. Post-operative care instructions were provided as previously described.

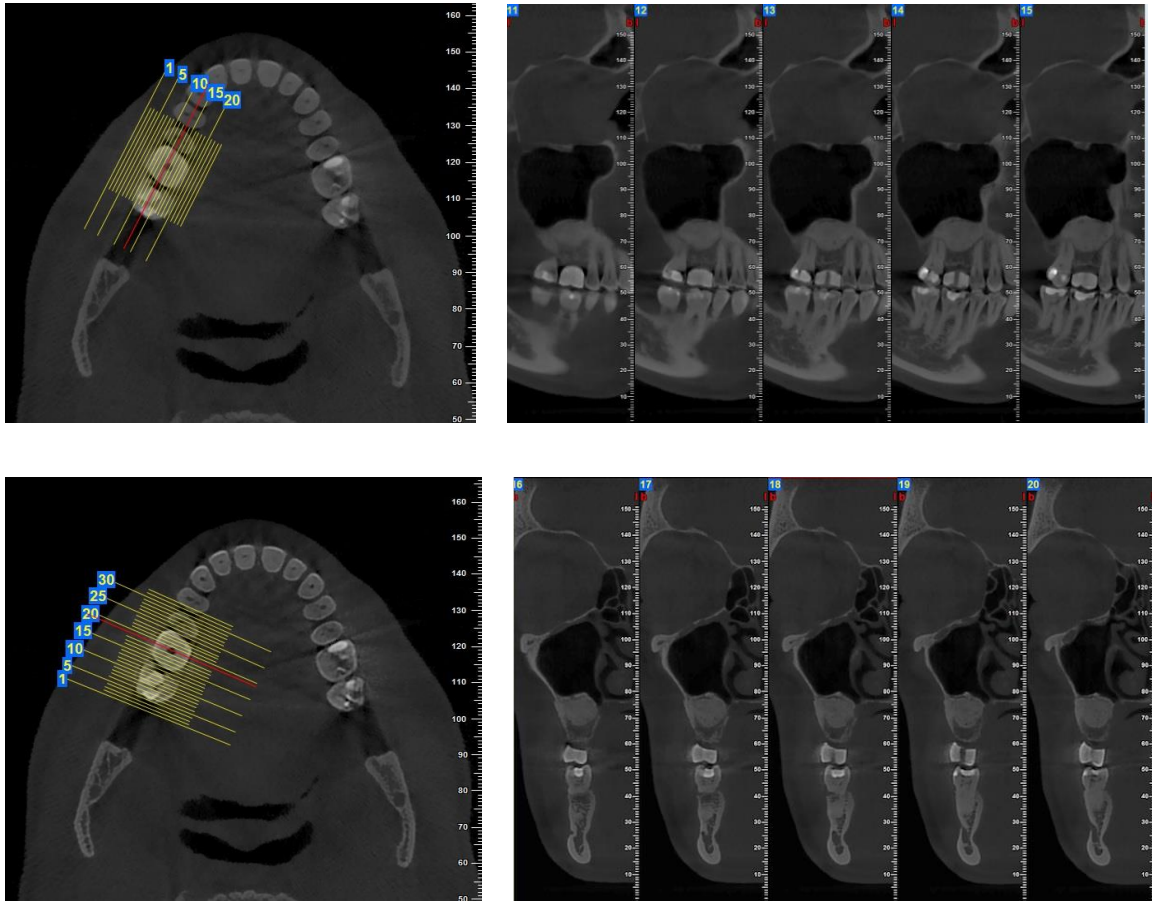


Figure 10. Post-operative CBCT image

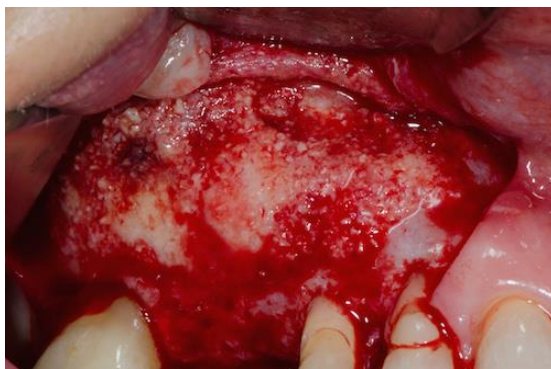

Figure 11. Appearance of lateral window following 9 months of healing in Group A.

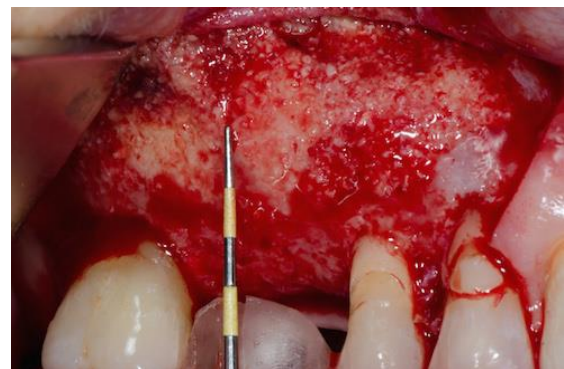

Figure 12. Locating the area for biopsy using a periodontal probe and the template.



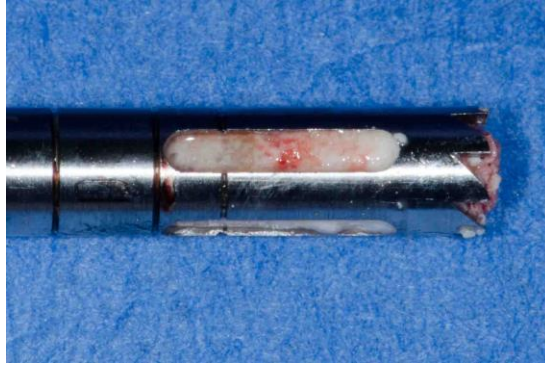


Figure 13. Bone core in a trephine (Bio-Oss®)

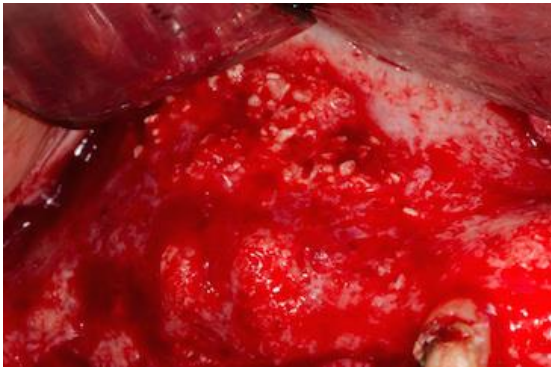

Figure 14. Appearance of lateral window following 9 months of healing in Group B.

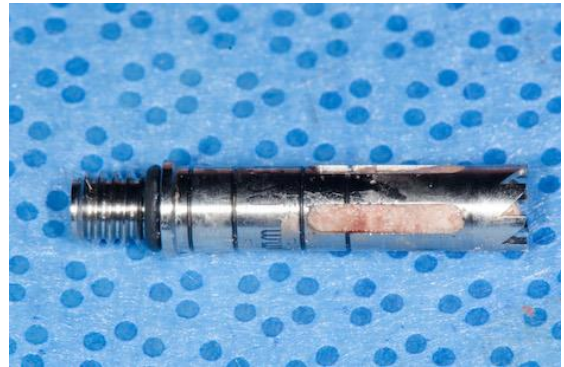

Figure 15. Bone core in a trephine (Equimatrix®)

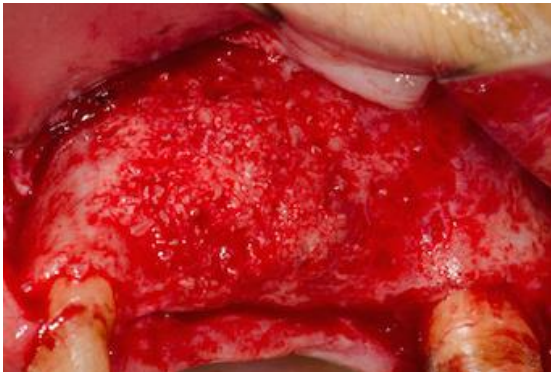


Figure 16. Appearance of lateral window following 9 months of healing in Group C



Figure 17. Bone core in a trephine (OSSIF-i sem™)

## **Histology**

All 28 specimens were sent to the Hard Tissue Research Laboratory, University of Minnesota School of Dentistry for histomorphometric analysis. Each specimen was numerically coded and stored in an individual container so that the patient's information remained confidential and that examiners were blinded. Non-decalcified histologic processing for histological evaluation was performed according to the method of Donath and Breuner (Donath & Breuner 1982; Rohrer MD, Schubert 1992). The specimens were dehydrated with graded series of alcohols (Decon Labs, Inc. King of Prussia, PA) for approximately 3 - 4 weeks. Following dehydration, the specimens were embedded in specialized Kulzer 7200 light polymerizing resin approximately for 10 hours (Technovit 7200 VLC; Kulzer, Friedrichsdorf, Germany) and were cut in a longitudinal section through the center of the core to a thickness of 150  $\mu\text{m}$  on an Exakt cutting/grinding system (Exakt Apparatebau, Norderstedt, Germany). Following this, the samples were grinded and hand polished to a thickness of 45-50  $\mu\text{m}$  using the Exakt microgrinding system, and they were stained with Stevenel's blue and Van Gieson picro fuchsin. Two slides were made from each of the specimens unless there are extenuating circumstances for a specific specimen making it possible to only produce one acceptable slide. The percentages of vital, non-vital bone and non-bone components were quantified using computerized image analysis.

- Vital bone stains bright red with variations in intensity depending on the maturity of the bone
- Non-vital bone and osteoid stain bright green
- Nuclei of cells, including osteoblasts, osteoclasts and osteocytes, stain blue.

- Connective tissue stains various shades of green.
- Non-biologic materials such as ceramic material, hydroxyapatite, membranes, etc., are not affected by the stain and are easily visualized and analyzed.

### **Histomorphometric Analysis**

All specimens were digitized at the same magnification using a NIKON ECLIPSE 50i microscope (Nikon corporation, JAPAN) and a SPOT INSIGHT 2 mega sample digital camera (Diagnostic instruments Inc, USA). Histomorphometric measurements were completed using a combination of SPOT 5.1 Advanced Software (Diagnostic instruments Inc, USA) and Adobe PhotoShop (Adobe Systems, Inc., San Jose, CA). The measurements to be obtained and presented in tabular form are:

1. Percentage of the area of the core, which is bone. Of the bone, the percentage of vital and non-vital bone (Allograft).
2. Percentage of non-bone material, which is the residual graft materials (Xenograft).
3. Percentage of connective tissue and marrow.

The histomorphometric data for each specimen was recorded as the average of the two slides from the specimen.

### **Statistical Analysis**

Non-parametric, Kruskal-Wallis test was used to compare the percentage of vital bone formation (VB%), the percentage of residual graft material (RGM%) and the percentage of connective tissue/marrow (CT%) independently among three groups. Post-hoc comparisons were conducted with Dunn- Bonferroni pairwise tests. The null

hypothesis for Kruskal-Wallis assumed no statistically significant difference in the amount of new bone formation. All hypotheses tests were two-sided and tested at an alpha level of 0.05 using Statistical package for the social science (SPSS) version 22 (SPSS<sup>®</sup>, IL).

## **CHAPTER THREE**

### **RESULTS**

#### **Clinical Results**

Twenty-one patients with 31 maxillary sinuses were originally included in this study (Table 1). Two patients with 3 sinuses were excluded during the course of the study. Three sinuses (two patients) were excluded due to infection (sample A-6) and failure to comply with follow-up appointments (A-10 and B-9).

A total of 19 patients (9 males and 10 females) with 28 sinuses (12 unilateral and 8 bilateral) with a mean age of 61.5 (ranged 33 - 75) remained in the study (Table 1). One bone core was obtained from each sinus resulting in a total of 28 bone cores harvested for biopsy with a mean healing time of 9.1 months (ranged 7.6 - 12.3) (Table 2).

Type 2 and 3 bone was more commonly observed for Group A (8/9 88.8%) and Group B (7/9 77.8%), while Type 3 and 4 was observed in Group C (10/10 100%) during biopsy using the trephine bur (Table 3).

Six maxillary sinus membrane perforations were encountered during surgery (A-2, A-7, A-8, B-10, C-5, C-6) [21.4% (6/28)]. All sites were repaired with using resorbable collagen membranes (Bio-Gide) and the MSG procedures were completed without further complications (Table 2).

One patient who underwent bilateral sinus grafts (B-7 and C-8) presented with suture breakdown resulting in two areas of approximately 3x15mm of granulation tissue two weeks following surgery. No signs of infection were noted and complete wound closure was noted at the one-month follow-up (Table 2).



**Table 1.** Patient demographics and surgical site distribution

<b>Sample Number</b>	<b>Gender</b>	<b>Age</b>	<b>Site</b>
<b>Group A</b>			
A-1	F	58	UR
A-2	M	71	UL
A-3	M	58	UL
A-4	M	72	UL
A-5	M	75	UR
A-6*	F	63	UR
A-7	F	66	UL
A-8	F	33	UL
A-9	F	55	UR
A-10 **	M	52	UL
A-11	F	65	UR
<b>Group B</b>			
B-1	M	61	UL
B-2	M	58	UR
B-3	M	72	UR
B-4	M	69	UR
B-5	F	54	UR
B-6	F	65	UL
B-7	M	70	UR
B-8	M	72	UL
B-9 **	M	52	UR
B-10	F	69	UL
<b>Group C</b>			
C-1	F	35	UR
C-2	F	55	UR
C-3	M	29	UR
C-4	M	75	UL
C-5	F	63	UL
C-6	M	69	UL
C-7	F	54	UL
C-8	M	70	UL
C-9	F	69	UR
C-10	M	60	UR

\* The sinus was excluded from the study due to infection

\*\* The sinus was excluded from study due to patient failure to comply with follow-up appointments

**Table 2.** Intraoperative and postoperative complications

Sample Number	Membrane Perforation	Perforation size (mm)	Postoperative complications
<b>Group A</b>			
A-1	-		
A-2	Yes	2 x 3	
A-3	-		
A-4	-		
A-5	-		
A-6*	-		Infection (graft removal)
A-7	Yes	1.5 x 1	
A-8	Yes	1 x 1	
A-9	-		
A-10	-		
A-11	-		
<b>Group B</b>			
B-1	-		
B-2	-		
B-3	-		
B-4	-		
B-5	-		
B-6	-		
B-7	-		Suture breakdown
B-8	-		
B-9	-		
B-10	Yes	2 x 2	
<b>Group C</b>			
C-1	-		
C-2	-		
C-3	-		
C-4	-		
C-5	Yes	2 x 4	
C-6	Yes	3 x 5	
C-7	-		
C-8	-		Suture breakdown
C-9	-		
C-10	-		

\* The sinus was excluded from the study due to infection

**Table 3.** Bone quality during biopsy at grafted sites

<b>Bone Quality</b>	<b>Group A</b>	<b>Group B</b>	<b>Group C</b>	<b>Total</b>
<b>Type 1</b>	0	0	0	0
<b>Type 2</b>	3	1	0	4
<b>Type 3</b>	5	6	5	16
<b>Type 4</b>	1	2	5	8

Classification of bone quality by Lekholm & Zarb (1985)

### **Results: Histomorphometric Analysis**

All harvested cores were analyzed through histomorphometric analysis. The mean healing time for the biopsy for Group A, B and C was 9.4 months (ranged 7.6 - 11.3), 8.7 months (ranged 8.1 - 10.7), and 9.2 months (ranged 7.6 - 12.3), respectively (Table 4).

Statistically significant differences were observed among all three groups in VB%, RBM%, and CT% [Kruskal Wallis,  $P = .001$ ,  $P < .001$ ,  $P = .028$ , respectively].

Insignificant difference in VB% was noted between Group A ( $10.9 \pm 8.9\%$ ) and Group B ( $9.1 \pm 5.9\%$ ) [ $P = 1.0$ ], but both were significantly less than Group C ( $32.0 \pm 12.4\%$ ) [ $P = .004$ ; Group A,  $P = .001$ ; Group B].

No significant difference in RBM% was observed between Group A ( $34.3 \pm 12.1\%$ ) and Group B ( $38.9 \pm 5.3\%$ ) [ $P = 1.0$ ], but both were significantly higher than Group C ( $5.5 \pm 5.7\%$ ) [ $P = .005$ ; Group A,  $P = .003$ ; Group B].

Likewise, no significant difference in CT% was observed between Group A ( $54.8 \pm 7.7\%$ ) and Group B ( $52.0 \pm 6.1\%$ ) [ $P = 1.0$ ], and Group A and Group C ( $62.5 \pm 9.8\%$ ) [ $P = .179$ ], but Group C was significantly higher than Group B [ $P = .031$ ].

**Table 4.** Histomorphometric analysis of the three groups of graft materials

<b>Sample Number</b>	<b>Healing Time (Months)</b>	<b>Vital Bone Volume (%)</b>	<b>Residual Graft Material (%)</b>	<b>Connective Tissue / Marrow (%)</b>
<b>Group A</b>				
A-1	9.0	7.6	38.5	53.9
A-2	11.3	8.1	44.7	46.9
A-3	8.6	17.7	32.5	49.8
A-4	10.7	5.1	35.8	59.1
A-5	7.6	1.5	34.2	64.3
A-7	8.3	0.1	43.7	56.2
A-8	10.3	28.3	3.9	67.8
A-9	8.4	14.0	39.0	47.0
A-11	10.3	15.2	36.8	48.0
Mean	9.4			
<b>Group B</b>				
B-1	7.9	2.4	35.6	62.0
B-2	8.6	11.9	35.1	53.0
B-3	10.7	10.2	38.3	51.5
B-4	8.2	3.5	41.5	55.0
B-5	9.2	7.2	38.2	54.6
B-6	8.2	12.1	47.1	40.9
B-7	9.0	14.7	31.0	54.3
B-8	8.1	1.7	46.5	51.8
B-10	8.6	18.6	36.4	45.0
Mean	8.7			
<b>Group C</b>				
C-1	9.5	30.1	7.4	62.4
C-2	8.4	28.1	6.0	65.9
C-3	12.3	56.4	0	43.6
C-4	7.6	34.3	6.4	59.3
C-5	9.4	33.1	10.1	56.8
C-6	8.2	22.4	0	77.6
C-7	9.2	29.9	6.7	61.8
C-8	9.0	30.1	0	69.9
C-9	8.6	45.1	0	54.9
C-10	9.3	10.0	17.3	72.7
Mean	9.2			
Overall	9.1			

**Table 5.** Histomorphometric comparison of the percentage of vital bone, residual bone material and connective tissue/marrow among the groups

<sup>a,b</sup>: different letters denote statistically significant difference using Dunn-Bonferroni pairwise tests at  $\alpha = .05$

	<b>Group A</b>	<b>Group B</b>	<b>Group C</b>	<b>P value</b>
	Mean $\pm$ SD	Mean $\pm$ SD	Mean $\pm$ SD	
<b>VB%</b>	10.9 $\pm$ 8.9 <sup>a</sup>	9.1 $\pm$ 5.9 <sup>a</sup>	32.0 $\pm$ 12.4 <sup>b</sup>	P = .001
<b>RBM%</b>	34.3 $\pm$ 12.1 <sup>a</sup>	38.9 $\pm$ 5.3 <sup>a</sup>	5.5 $\pm$ 5.7 <sup>b</sup>	P < .001
<b>CT%</b>	54.8 $\pm$ 7.7 <sup>a,b</sup>	52.0 $\pm$ 6.1 <sup>a</sup>	62.5 $\pm$ 9.8 <sup>b</sup>	P = .028

## **Results: Histologic Analysis**

Common findings among the three groups were follows: 1) specimens showed varying amounts of new bone formation and bone maturation; 2) areas of newly formed bone bridged well between residual bone graft particles. This histologic observation demonstrated that all graft materials used in the study appeared to have osteoconductive properties.

### ***Group A***

Residual ABBM particles remained scattered in the field and easily distinguished from vital bone. Newly formed bone interconnected particle to particle (Figure 18). At high magnification, intimate contact was noted between the newly formed bone and the residual bone particles (Figure 19). At very high magnification, osteoid was present along the new bone interface in some areas, indicating the process of new bone formation. Osteoblasts were observed in the front line of the newly formed bone. Abundant vascular structures, blood cells, and fibroblasts were observed in the connective tissue spaces (Figure 19, 20). In one sample (A-7), fibrous tissue encapsulation of particles was observed in most of the field, which appeared to prevent from any new bone formation.

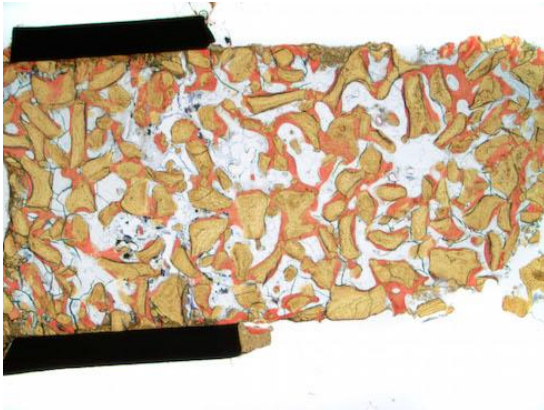

Figure 18. (Magnification  $\times 25$ )

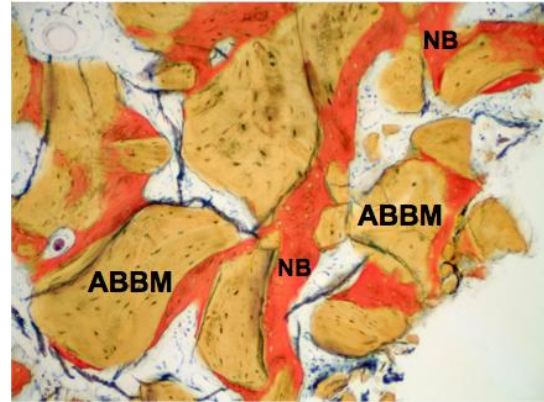


Figure 19. ( $\times 100$ )

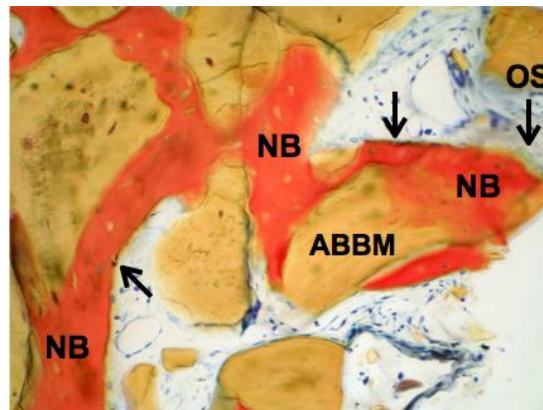


Figure 20. ( $\times 200$ )

Figure 18-20. Photomicrographs of ABBM. Newly formed bone (NB) interconnects bone particles (ABBM) throughout the field. Osteoblasts (arrow) and osteoid (OS) are observed in contiguity with the newly formed bone. Abundant vascular structures are evident in the connective tissue space. (Stevenel's blue and Van Gieson's picro fuchsin stain).

### ***Group B***

The histological appearance of AEBM was similar to the one observed in ABBM (Figure. 21). Residual bone particles were easily distinguishable from vital bone. Newly formed bone was in close contact with the graft particles and interconnecting with various levels of bone maturation. Lines of osteoblasts were observed at the interface of

the newly formed bone. Abundant vascular structures were present in connective tissue spaces (Figure. 22, 23).

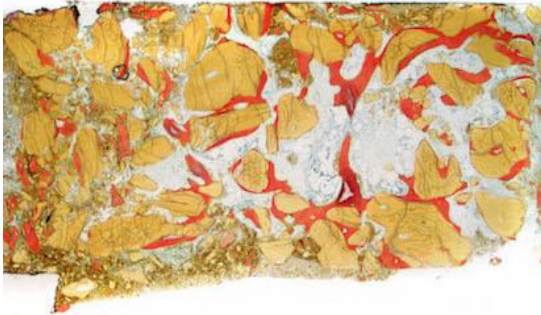
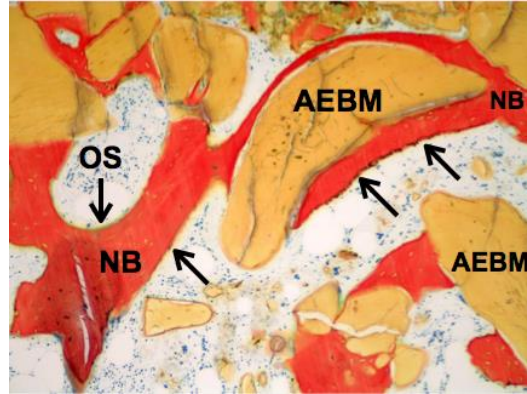


Figure 21.



(Magnification  $\times 25$ )

Figure 22.

( $\times 100$ )

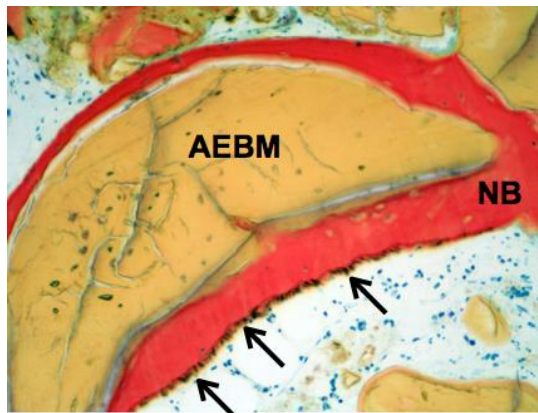


Figure 23.

( $\times 200$ )

Figure 21-23. Photomicrographs of AEBM. Newly formed bone (NB) shows in direct contact to AEBM and interconnects residual bone particles similar to ABBM. Osteoblast line (arrow), osteoid (OS), and vascular structures are seen. (Stevenel's blue and Van Gieson's picro fuchsin stain).

### *Group C*

The MCBA demonstrated different histological findings from the previous two groups (Figure. 24). Residual graft particles were bridged by vital bone with intimate



contact (Figure. 25). The bone particles were replaced with vital bone and was difficult to distinguish the residual bone particles from newly formed bone. Osteoblasts were observed along with new bone formation (Figure. 26).

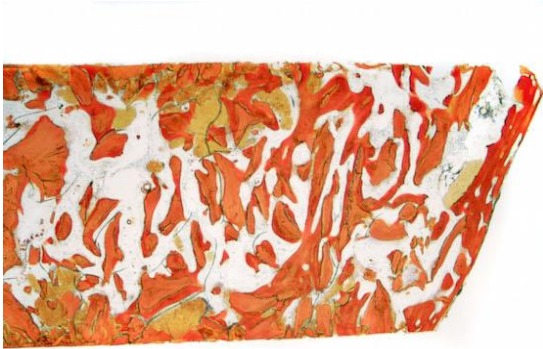

Figure 24. (Magnification  $\times 25$ )

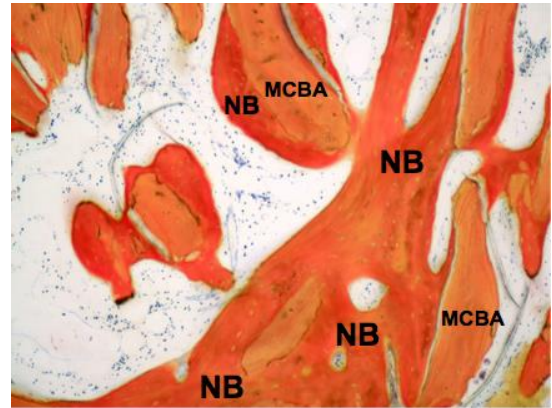


Figure 25. ( $\times 100$ )

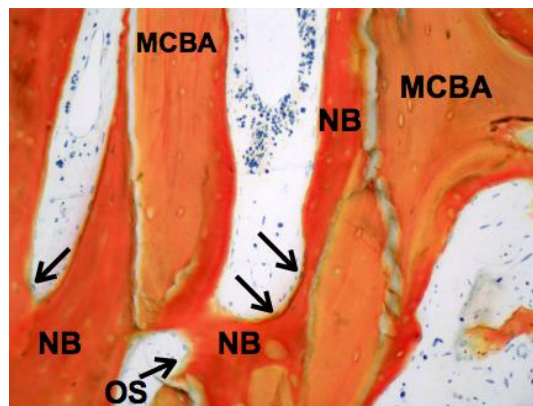


Figure 26. ( $\times 200$ )

Figure 24-26. Photomicrograph of MCBA. Newly formed bone (NB) is in intimate contact to MCBA and bridges residual bone particles as same as ABBM or AEBM. Osteoblasts (arrow), osteoid (OS), and vascular structures are seen in the connective tissue (Stevenel's blue and Van Gieson's picro fuchsin).

## CHAPTER FOUR

### DISCUSSION AND CONCLUSIONS

#### Discussion

One of the methods in evaluating the performance of a graft material for MSG is by histomorphometric analysis, which quantifies the percentage of vital bone formation after healing as well as the percentage of residual bone materials and connective tissue/marrow. Nevertheless, numerous factors can affect the histomorphometric outcome of these graft materials following the MSG. These factors are; graft materials used, location of bone core harvested, biopsy harvesting time, quality of grafted bone, presence of membrane to conceal the lateral sinus window, complications as well as operator experience.

In this histomorphometric study, two xenograft materials (Group A {ABBM}, [Bio-Oss<sup>®</sup>], Group B, {AEBM}, [Equimatrix<sup>®</sup>]) and one allograft material (Group C {MCBA}, [OSSIF-i sem<sup>™</sup>]) were evaluated. There is insignificant difference in the mean VB% between ABBM ( $10.9 \pm 8.9\%$ ) and AEBM ( $9.1 \pm 5.9\%$ ), but both were significantly less than MCBA ( $32.0 \pm 12.4\%$ ) at a mean healing time of 9.1 months. The VB% of allograft tends to outperform xenograft because of the greater graft turnover with allograft. The mean VB% of ABBM (10.9%) and AEBM (9.1%) in this study is much lower, when compared to other studies evaluating the mean of VB% using ABBM [23.0% (0 - 53%)] and AEBM [23.4%]. (Yildirim et al. 2000; Wallace et al. 2005; Froum et al. 2006, 2013c; Lee et al. 2006; Mangano et al. 2007; Cordaro et al. 2008; Simunek et al. 2008; Choi et al. 2009; Chackartchi et al. 2011; Kolerman et al. 2012; Pettinicchio et al. 2012; Kao et al. 2012; Testori et al. 2013; Kohal et al. 2015) (Nevins et al. 2013). On the other hand, the mean VB% for the MCBA in this study was similar to other studies

using allograft (Puros<sup>®</sup> and others) (29% [0 - 54.8%]) as a bone graft material (Noumbissi et al. 2005; Kolerman et al. 2008, 2012; Froum et al. 2006; Soardi et al. 2011; Avil-Ortez et al. 2012). It is interesting to note that, VB% of healed MSG tends to vary significantly regardless xenografts (0 - 53%) or allografts (0 - 54%). In this study, the mean RBM% in ABBM ( $34.3 \pm 12.1\%$ ) and AEBM ( $38.9 \pm 5.3\%$ ) was significantly greater than the mean RBM% in MCBA ( $5.5 \pm 5.7\%$ ). This is because of the slow or non-turnover characteristics of xenograft when compared with allograft. In fact, in a study in which bone core was harvested and evaluated at 6 months and 11 years after ABBM was used for MSG, ABBM particles were still observed at 11 years follow-up. Furthermore, the RBM% remained similar the two time frames (Mordenfeld et al. 2014). The mean CT% for ABBM ( $54.8 \pm 7.7\%$ ), AEBM ( $52.0 \pm 6.1\%$ ) and MCBA ( $62.5 \pm 9.8\%$ ) in this study is similarly high. However, human native bone has been reported with similarly high CT% (47.2 - 75.5%) (Valentini et al. 2000; Galindo-Moreno et al. 2009; Tosta et al. 2013).

The two common locations to harvest biopsy cores for grafted maxillary sinus are either through the alveolar crest or the lateral window. The VB% of cores harvested via lateral window in studies evaluated ABBM [20% (0 - 53%)] (Wallace et al. 2005; Froum et al. 2006, 2013c; Simunek et al. 2008; Choi et al. 2009; Kao et al. 2012; Testori et al. 2013) as well as MCBA graft materials [25% (0 - 51%)] (Froum et al. 2006, 2013a) tend to be slightly less, when compared to the VB% in studies harvested via the alveolar crest using ABBM [26% (4.1 - 45.2%)] (Valentini et al. 2000; Yildirim et al. 2000; Lee et al. 2006; Cordaro et al. 2008; Chackartchi et al. 2011; Kolerman et al. 2012; Pettinicchio et al. 2012; Di Stefano et al. 2015) as well as allograft (30% [0 - 54.8%]) (Noumbissi et al.

2005; Kolerman et al. 2008, 2012; Soardi et al. 2011; Avil-Ortez et al. 2012). This is because the biopsy harvested from alveolar crest may include some native bone, which may lead to greater VB%. Because of that, in this study, biopsy core was harvested from the lateral window.

In this study, biopsy core were harvested approximately 8 months or more after MSG. Hanisch et al., harvested biopsy cores from grafted maxillary sinus at 6, 8, 10, or 12 months for histomorphometric analysis, reported the VB% was significantly greater at 12 months as compared to at 6 or 8 months and the VB% increased up to 12 months (Hanisch et al. 1999). Although there was a great ranged of biopsy harvesting time from 7.6 to 12.3 months in this study, there was no statistically significant correlation between the overall biopsy harvesting time and the VB% in all groups; ABBA (7.6-11.3 months) [ $P = .330$ ], AEEM (8.0-10.7 months) [ $P = .175$ ] and MCBA (7.6-12.3 months) [ $P = .197$ ].

In this study, Type 2 and Type 3 bone were more commonly encountered during biopsy for ABBA and AEEM, while Type 3 and Type 4 bone were only encountered in MCBA (Table 3). It is interesting to note the high VB% (32.0%) in MCBA did not translate into high drill resistance or high bone quality. The greater drill resistance for ABBA and AEEM can be caused by the high RBM%. In fact, residual bone graft particles in xenograft in grafted maxillary sinus can increase bone density thereby increasing drill resistance (Valentini et al. 2000).

The need of resorbable membrane on the lateral window during MSG is controversial (Tarnow et al. 2000; Wallace & Froum 2003; Pjetursson et al. 2008; Garcia-Denche et al. 2013; Suárez-López Del Amo et al. 2015). Resorbable membrane has been shown to be effective in reducing connective tissue proliferation, though it has little

significant on new bone formation (Choi et al. 2009; Barone et al. 2013). However, studies showed similar CT% when evaluated grafted maxillary sinus using ABBM (45% [24.7 - 74.7%]) (Yildirim et al. 2000; Wallace et al. 2005; Froum et al. 2006, 2013c; Lee et al. 2006; Cordaro et al. 2008; Choi et al. 2009; Chackartchi et al. 2011; Kolerman et al. 2012; Garcia-Denche et al. 2013; Testori et al. 2013; Kohal et al. 2015) when compared to ABBA without membrane (43% [33.0 - 78%]) (Valentini et al. 2000; Wallace et al. 2005; Mangano et al. 2007; Choi et al. 2009; Pettinicchio et al. 2012). The mean CT% in studies using MCBA with membrane showed 56% [40 - 79%]. Despite the use of resorbable membrane, the CT% in this study in ABBM (54.8%) and MCBA (62.5%) was slightly higher than aforementioned studies. Regardless, this is still within the range of the published CT% with membrane with xenografts (24.7 - 74.7%) or allografts (40 - 79%), as well as in human native bone (47.2 - 75.5%).

The rate of maxillary sinus membrane perforations was 6/28 (21.4%) in this study, which is similar to the rate (19.5%) reported in a systematic review by Pjetursson et al. (Pjetursson et al. 2008). Although maxillary sinus membrane perforations can be associated with an increase in post-operative complications such as sinusitis, infection, and/or graft failure (Schwartz-Arad et al. 2004; Nolan et al. 2014), Froum et al. reported that properly repaired small to middle size perforation (<10 mm) did not have any adverse effect on vital bone formation (Froum et al. 2013b). Similarly, the mean VB% (18.4%) does not seem to be compromised when small controlled perforations (< 5mm) were repaired with resorbable membrane in this study.

## Conclusions

Within the confines of this study, a statistically significant difference in new bone formation was noted among the three graft materials at a mean follow-up period of 9.1 months following MSG. The MCBA (OSSIF-i sem™) group revealed significantly greater new bone formation when compared to the ABBM (Bio-Oss®) and AEBM (Equimatrix®) groups. The AEBM showed comparable histomorphometric results in all parameters (VB%, RBM%, CT) when compared to ABBM. Bone quality was greater in ABBA and AEBM groups in comparison to the MCBA group indicating the greater VB% does not directly translate to improved bone quality.

## REFERENCES

- Aghaloo T.L., Moy P.K. (2007). Which hard tissue augmentation techniques are the most successful in furnishing bony support for implant placement? *Int J Oral Maxillofac Implants*, 22 Suppl, 49-70.
- Artese L., Piattelli A., Di Stefano D.A., Piccirilli M., Pagnutti S., D'Alimonte E., Perrotti V. (2011). Sinus lift with autologous bone alone or in addition to equine bone: an immunohistochemical study in man. *Implant Dent*, 20, 383-388.
- Avila-Ortiz G., Wang H.L., Galindo-Moreno P., Misch C.E., Rudek I., Neiva R. (2012). Influence of lateral window dimensions on vital bone formation following maxillary sinus augmentation. *Int J Oral Maxillofac Implants*, 27, 1230-1238.
- Barone A., Ricci M., Grassi R.F., Nannmark U., Quaranta A., Covani U. (2013). A 6-month histological analysis on maxillary sinus augmentation with and without use of collagen membranes over the osteotomy window: randomized clinical trial. *Clin Oral Implants Res*, 24, 1-6.
- Boyne P.J., James R.A. (1980). Grafting of the maxillary sinus floor with autogenous marrow and bone. *J Oral Surg*, 38, 613-616.
- Chackartchi T., Iezzi G., Goldstein M., Klinger A., Soskolne A., Piattelli A., Shapira L. (2011). Sinus floor augmentation using large (1-2 mm) or small (0.25-1 mm) bovine bone mineral particles: a prospective, intra-individual controlled clinical, micro-computerized tomography and histomorphometric study. *Clin Oral Implants. Res*, 22, 473-480.
- Choi K.S., Kan J.Y., Boyne P.J., Goodacre C.J., Lozada J.L., Rungcharassaeng K. (2009). The effects of resorbable membrane on human maxillary sinus graft: a pilot study. *Int. J Oral Maxillofac Implants*, 24, 73-80.
- Cordaro L., Bosshardt D.D., Palattella P., Rao W., Serino G., Chiapasco M. (2008). Maxillary sinus grafting with Bio-Oss or Straumann Bone Ceramic: histomorphometric results from a randomized controlled multicenter clinical trial. *Clin Oral Implants Res*, 19, 796-803.
- Crespi R., Vinci R., Capparè P., Gherlone E., Romanos G.E. (2007). Calvarial versus iliac crest for autologous bone graft material for a sinus lift procedure: a histomorphometric study. *Int J Oral Maxillofac Implants*, 22, 527-532.
- Del Fabbro M., Wallace S.S., Testori T. (2013). Long-term implant survival in the grafted maxillary sinus: a systematic review. *Int J Periodontics Restorative Dent*, 33, 773-783.
- Di Stefano D.A., Gastaldi G., Vinci R., Cinci L., Pieri L., Gherlone E. (2015). Histomorphometric comparison of enzyme-deantigenic equine bone and

- anorganic bovine bone in sinus augmentation: a randomized clinical trial with 3-year follow-up. *Int J Oral Maxillofac Implants*, 30, 1161-1167.
- Di Stefano D.A., Gastaldi G., Vinci R., Polizzi E.M., Cinci L., Pieri L., Gherlone E. (2016). Bone formation following sinus augmentation with an equine-derived bone graft: a retrospective histologic and histomorphometric study with 36-month follow-up. *Int J Oral Maxillofac Implants*, 31, 406-412.
- Donath K., Breuner G. (1982). A method for the study of undecalcified bones and teeth with the attached soft tissues. The Sage- Schliff (sawing and grinding) techniques. *J Oral Pathol*, 11, 318-326.
- Froum S.J., Wallace S.S., Elian N., Cho S.C., Tarnow D.P. (2006). Comparison of mineralized cancellous bone allograft (Puros) and anorganic bovine bone matrix (Bio-Oss) for sinus augmentation: histomorphometry at 26 to 32 weeks after grafting. *Int J Periodontics Restorative Dent*, 26, 543-551.
- Froum S.J., Wallace S.S., Cho S.C., Rosenburg E., Froum S., Schoor R., Mascarenhas P., Tarnow D.P., Corby P., Elian N., Fickl S., Ricci J., Hu B., Bromage T., Khouly I. (2013a). A histomorphometric comparison of Bio-Oss alone versus Bio-Oss and platelet-derived growth factor for sinus augmentation: a postsurgical assessment. *Int J Periodontics Restorative Dent*, 33, 269-279.
- Froum S.J., Khouly I., Favero G., Cho S.C. (2013b). Effect of maxillary sinus membrane perforation on vital bone formation and implant survival: a retrospective study. *J Periodontol*, 84, 1094-1099.
- Froum S.J., Wallace S., Cho S.C., Rosenburg E., Froum S., Schoor R., Mascarenhas P., Tarnow D.P., Corby P., Elian N., Fickl S., Ricci J., Hu B., Bromage T., Khouly I. (2013c). A histomorphometric comparison of Bio-Oss alone versus Bio-Oss and platelet-derived growth factor for sinus augmentation: a postsurgical assessment. *Int J Periodontics Restorative Dent*, 33, 269-279.
- Galindo-Moreno P., Padial-Molina M., Fernández-Barbero J.E., Mesa F., Rodríguez-Martínez D., O'Valle F. (2009). Optimal microvessel density from composite graft of autogenous maxillary cortical bone and anorganic bovine bone in sinus grafts: influence of clinical variables. *Clin Oral Implants Res*, 21, 221-227.
- García-Denche J.T., Wu X., Martinez P.P, Eimar H., Ikbal D.J., Hernández G., López-Cabarcos E., Fernandez-Tresguerres I., Tamimi F. (2013). Membranes over the lateral window in sinus augmentation procedures: a two-arm and split-mouth randomized clinical trials. *J Clin Periodontol*, 40, 1043-1051.
- Hallman M., Sennerby L., Lundgren S. (2002). A clinical and histologic evaluation of implant integration in the posterior maxilla after sinus floor augmentation with autogenous bone, bovine hydroxyapatite, or a 20:80 mixture. *Int J Oral Maxillofac Implants*, 17, 635-643.



- Hanisch O., Lozada J.L., Holmes R.E., Calhoun C.J., Kan J.Y., Spiekermann H. (1999). Maxillary sinus augmentation prior to placement of endosseous implants: A histomorphometric analysis. *Int J Oral Maxillofac Implants*, 14, 329-336.
- Hirsch J.M., Ericsson I. (1991). Maxillary sinus augmentation using mandibular bone grafts and simultaneous installation of implants. A surgical technique. *Clin Oral Implants Res*, 2, 91-96.
- Jensen J., Simonsen E.K., Sindet-Pederson S. (1990). Reconstruction of the severely resorbed maxilla with bone grafting and osseointegrated implants: a preliminary report. *J Oral Maxillofac Surg*, 48, 27-32.
- Jensen O.T., Shulman L. B., Block M.S., Iacono V.J. (1998). Report of the Sinus Consensus Conference of 1996. *Int J Oral Maxillofac Implants*, 13, 11-45.
- Jensen T., Schou S, Stavropoulos A., Terheyden H., Holmstrup P. (2012). Maxillary sinus floor augmentation with Bio-Oss or Bio-Oss mixed with autogenous bone as graft: a systematic review. *Clin Oral Implants Res*, 23, 263-273.
- Johansson B., Grepe A., Wannfors K., Hirsch J.M. (2001). A clinical study of changes in the volume of bone grafts in the atrophic maxilla. *Dentomaxillofac Radiol*, 30, 157-161.
- Kalk, W.W., Raghoobar, G.M., Jansma, J. & Boering, G. (1996). Morbidity from iliac crest bone harvesting. *J Oral and Maxillofac Surg*, 54, 1424-1429.
- Kao D.W., Kubota A., Nevins M., Fiorellini J.P. (2012). The negative effect of combining rhBMP-2 and Bio-Oss on bone formation for maxillary sinus augmentation. *Int J Periodontics Restorative Dent*, 32, 61-67.
- Kent J.N., Block M.S. (1989). Simultaneous maxillary sinus floor bone grafting and placement of hydroxylapatite-coated implants. *J Oral Maxillofac Surg*, 47, 238-242.
- Kohal R.J., Gubik S., Strohl C., Stampf S., Bächle M., Hurrle A.A., Patzelt S.B. (2015). Effect of two different healing times on the mineralization of newly formed bone using a bovine bone substitute in sinus floor augmentation: a randomized, controlled, clinical and histological investigation. *J Clin Periodontol*, 42, 1052-1059.
- Kolerman R., Tal H., Moses O. (2008). Histomorphometric analysis of newly formed bone after maxillary sinus floor augmentation using ground cortical bone allograft and internal collagen membrane. *J Periodontol*, 79, 2104-2111.
- Kolerman R., Samorodnitzky-Naveh G.R., Barnea E., Tal H. (2012). Histomorphometric analysis of newly formed bone after bilateral maxillary sinus augmentation using two different osteoconductive materials and internal collagen membrane. *Int J Periodontics Restorative Dent*, 32, e21-28.

- Lee Y.M., Shin S.Y., Kim J.Y., Kye S.B., Ku Y., Rhyu I.C. (2006). Bone reaction to bovine hydroxyapatite for maxillary sinus floor augmentation: histologic results in humans. *Int J Periodontics Restorative Dent*, 26, 471-481.
- Lekholm U., Zarb G. (1985). Brånemark P-I., Zarb G., Albrektsson T. (Eds.), *Tissue integrated Prosthesis Osseointegration in Clinical Dentistry* (pp.199-209). Chicago: Quintessence.
- Lorenzetti M., Mozzati M., Campanino P.P., Valente G. (1998). Bone augmentation of the inferior floor of the maxillary sinus with autogenous bone or composite bone grafts: a histologic-histomorphometric preliminary report. *Int J Oral Maxillofac Implants*, 13, 69-76.
- Mangano C., Scarano A., Perrotti V., Iezzi G., Piattelli A. (2007). Maxillary sinus augmentation with a porous synthetic hydroxyapatite and bovine-derived hydroxyapatite: a comparative clinical and histologic study. *Int J Oral Maxillofac Implants*, 22, 980-986.
- Mordenfeld A., Johansson C.B., Albrektsson T., Hallman M. (2010). A randomized and controlled clinical trial of two different compositions of deproteinized bovine bone and autogenous bone used for lateral ridge augmentation. *Clin Oral Implants Res*, 25, 310-320.
- Moy P.K., Lundgren S., Holmes R.E. (1993) Maxillary sinus augmentation: histomorphometric analysis of graft materials for maxillary sinus floor augmentation. *J Oral Maxillofac Surg*, 51, 857-862.
- Nevins M., Heinemann F., Janke U.W., Lombardi T., Nisand D., Rocchietta I., Santoro G., Schupbach P., Kim D.M. (2013). Equine-derived bone mineral matrix for maxillary sinus floor augmentation: a clinical, radiographic, histologic, and histomorphometric case series. *Int J Periodontics Restorative Dent*, 33, 483-489.
- Nkenke, E., Schultze-Mosgau, S., Radespiel-Tröger, M., Kloss, F., Neukam, F.W. (2001). Morbidity of harvesting of chin grafts: a prospective study. *Clin Oral Implants. Res*, 12, 495-502.
- Nkenke, E., Weisbach, V., Winckler, E., Kessler, P., Schultze-Mosgau, S., Wiltfang, J., Neukam, F.W. (2004). Morbidity of harvesting of bone grafts from the iliac crest for preprosthetic augmentation procedures: a prospective study. *Int J Oral Maxillofac Surg*, 33, 157-163.
- Nolan P.J., Freeman K., Kraut R.A. (2014). Correlation between Schneiderian membrane perforation and sinus lift graft outcome: a retrospective evaluation of 359 augmented sinus. *J Oral Maxillofac Surg*, 72, 47-52.
- Noumbissi S.S., Lozada J.L., Boyne P.J., Rohrer M.D., Clem D., Kim J.S., Prasad H. (2005). Clinical, histologic, and histomorphometric evaluation of mineralized

- solvent-dehydrated bone allograft (Puros) in human maxillary sinus grafts. *J Oral Implantol*, 31, 171-179.
- Pettinicchio M., Traini T., Murmura G., Caputi S., Degidi M., Mangano C., Piattelli A. (2012). Histologic and histomorphometric results of three bone graft substitutes after sinus augmentation in humans. *Clin Oral Investig*, 16, 45-53.
- Piattelli, M., Favero, G.A., Scarano, A., Orsini, G. & Piattelli, A. (1999) Bone reactions to anorganic bovine bone (Bio-Oss) used in sinus augmentation procedures: a histologic long-term report of 20 cases in humans. *Int J Oral Maxillofac Implants*, 14, 835-840.
- Pjetursson B.E., Tan W.C., Zwahlen M., Lang N.P. (2008). A systematic review of the success of sinus floor elevation and survival of implants inserted in combination with sinus floor elevation. Part I: Lateral approach. *J Clin Periodontol*, 35, 216-240.
- Rohrer M.D., Schubert C.C. (1992). The cutting-grinding technique for histological preparation of undecalcified bone and bone- anchored implants: Improvement in instrumentation and procedures. *Oral Surg Oral Med Oral Pathol*, 74,73-78.
- Scarano A., Pecora G., Piattelli M., Piattelli A. (2004). Osseointegration in a sinus augmented with bovine porous mineral: histological results in an implant retrieved 4 years after insertion. a case report. *J Periodontol*, 75, 1161-1166.
- Scher E.L., Day R.B., Speight P.M. (1999). New bone formation after a sinus lift procedure using demineralized freeze-dried bone and tricalcium phosphate. *Implant Dent*, 8, 49-53.
- Schwartz-Arad D., Herzberg R., Dolev E. (2004). The prevalence of surgical complications of the sinus graft procedure and their impact on implant survival. *J Periodontol*, 75, 511-516.
- Simunek A., Kopecka D., Somanathan R.V., Pilathadka S., Brazda T. (2008). Deproteinized bovine bone versus beta-tricalcium phosphate in sinus augmentation surgery: a comparative histologic and histomorphometric study. *Int J Oral Maxillofac Implants*, 23, 935-942.
- Smiler D.G., Holmes R.E. (1987). Sinus lift procedure using porous hydroxyapatite: a preliminary clinical report. *J Oral Implantol*, 13, 239-253.
- Smiler D.G., Johnson P.W., Lozada J.L., Misch C., Rosenlicht J.L., Tatum O.H. Jr, Wagner J.R. (1992). Sinus lift grafts and endosseous implants. Treatment of the atrophic posterior maxilla. *Dent Clin North Am*, 36, 151-186.

- Soardi C.M., Spinato S., Zaffe D., Wang H.L. (2011). Atrophic maxillary floor augmentation by mineralized human bone allograft in sinuses of different size: a histologic and histomorphometric analysis. *Clin Oral Implants*, 22, 560-566.
- Suárez-López Del Amo F., Ortega-Oller I., Catena A., Monje A., Khoshkam V., Torrecillas-Martínez L., Wang H.L., Galindo-Moreno P. (2015). Effect of barrier membranes on the outcomes of maxillary sinus floor augmentation: a meta-analysis of histomorphometric outcomes. *Int J Oral Maxillofac Implants*, 30, 607-618.
- Tarnow D.P., Wallace S.S., Froum S.J., Rohrer M.D., Cho S.C. (2000). Histologic and clinical comparison of bilateral sinus floor elevations with and without barrier membrane placement in 12 patients: Part 3 of an ongoing prospective study. *Int J Periodontics Restorative Dent*, 20, 117-126.
- Testori T., Wallace S.S., Trisi P., Capelli M., Zuffetti F., Del Fabbro M. (2013). Effect of xenograft (ABBM) particle size on vital bone formation following maxillary sinus augmentation: a multicenter, randomized, controlled, clinical histomorphometric trial. *Int J Periodontics Restorative Dent*, 33, 467- 475.
- Tosta M., Cortes A.R., Correa L., Pinto D.S., Tumenas I., Katchburian E. (2013). Histologic and histomorphometric evaluation of a synthetic bone substitute for maxillary sinus grafting in humans. *Clin. Oral Impl. Res*, 24, 866-870.
- Traini T., Degidi M., Sammons R., Stanley P., Piattelli A. (2008). Histologic and elemental microanalytical study of anorganic bovine bone substitution following sinus floor augmentation in humans. *J Periodontol*, 79, 1232-1240.
- Valentini P., Abensur D., Densari D., Graziani J.N., Hammerle C.H.F. (1998). Histological evaluation of Bio-Oss® in a 2-stage sinus floor elevation and implantation procedure. A human case report. *Clin Oral Impl Res*, 9, 59-64.
- Valentini P., Abensur D., Wenz B., Peetz M., Schenfe R. (2000). Sinus grafting with porous bone mineral (Bio-Oss) for implant placement: a 5-year study on 15 patients. *Int J Periodontics Restorative Dent*, 20, 245-253.
- van den Bergh J.P., ten Bruggenkate C.M., Krekeler G., Tuinzing D.B. (2000). Maxillary sinus floor elevation and grafting with human demineralized freeze dried bone. *Clin Oral Implants Res*, 11, 487-493.
- Wallace S.S., Froum S.J., Tarnow D.P. (1996). Histologic evaluation of a sinus elevation procedure: a clinical report. *Int J Periodontics Restorative Dent*, 16, 46-51.
- Wallace S.S., Froum S.J. (2003). Effect of maxillary sinus augmentation on the survival of endosseous dental implants. A systemic review. *Ann Periodontol*, 8, 328-343.

Wallace S.S., Froum S.J., Cho S.C., Elian N., Monteiro D., Kim B.S., Tarnow D.P. (2005). Sinus augmentation utilizing anorganic bovine bone (Bio-Oss) with absorbable and nonabsorbable membranes placed over the lateral window: histomorphometric and clinical analyses. *Int J Periodontics Restorative Dent*, 25, 551-559.

Wheeler S.L. (1997). Sinus augmentation for dental implants: the use of alloplastic materials. *J Oral Maxillofac Surg*, 55, 1287-1293.

Wood R.M., Moore D.L. (1988). Grafting of the maxillary sinus with intra-orally harvested autogenous bone prior to implant placement. *Int J Oral Maxillofac Implants*, 3, 209-214.

Yildirim M., Spiekermann H., Biesterfeld S., Edelhoff D. (2000). Maxillary sinus augmentation using xenogenic bone substitute material Bio-Oss in combination with venous blood. A histologic and histomorphometric study in humans. *Clin Oral Implants Res*, 11, 217-229.